



# Standards for acquiring digital chest radiography images for medical surveillance of Queensland mine and quarry workers

Including technical guidelines for image quality  
assessment for ILO classification

DRAFT 17 July 2023

This publication has been compiled by Resources Safety & Health Queensland (RSHQ).

© Resources Safety & Health Queensland, 2023

RSHQ supports and encourages the dissemination and exchange of its information. The copyright in this publication is licensed under a Creative Commons Attribution 4.0 International (CC BY 4.0) licence.



Under this licence you are free, without having to seek our permission, to use this publication in accordance with the licence terms. You must keep intact the copyright notice and attribute RSHQ as the source of the publication.

Note: Some content in this publication may have different licence terms as indicated.

For more information on this licence, visit <https://creativecommons.org/licenses/by/4.0/>.

The information contained herein is subject to change without notice. RSHQ shall not be liable for technical or other errors or omissions contained herein. The reader/user accepts all risks and responsibility for losses, damages, costs and other consequences resulting directly or indirectly from using this information.

Interpreter statement: The Queensland Government is committed to providing accessible services to Queenslanders from all culturally and linguistically diverse backgrounds. If you have difficulty in understanding this document, you can contact us within Australia on 13QGOV (13 74 68) and we will arrange an interpreter to effectively communicate this guideline to you.

# Table of Contents

<b>Acknowledgement .....</b>	<b>6</b>
<b>Acronyms and abbreviations .....</b>	<b>6</b>
<b>Introduction.....</b>	<b>7</b>
1. Background .....	7
2. Purpose .....	7
<b>Part 1: Standards.....</b>	<b>9</b>
1. Government regulation.....	9
2. RANZCR and DIAS standards .....	9
3. Personnel .....	9
4. Imaging equipment and software .....	10
5. Image acquisition .....	11
6. Documentation .....	12
7. Quality assurance and control .....	13
<b>Part 2: Technical guidelines for X-ray image quality assessment for ILO classification .....</b>	<b>14</b>
1. Technical quality grading of images .....	14
2. Common difficulties .....	15
3. Examples of images and interpretation .....	17
<b>References .....</b>	<b>33</b>

## List of images

Image A – ILO Classification form Section 1 .....	15
Image B – Chest X-ray 1 .....	17
Image C – Chest X-ray 2 .....	18
Image D – Chest X-ray 3 .....	19
Image E – Chest X-ray 4 .....	20
Image F – Chest X-ray 5 .....	21
Image G – Chest X-ray 6 .....	22
Image H – Chest X-ray 7 .....	23
Image I – Chest X-ray 8 .....	24
Image J – Chest X-ray 9 .....	25
Image K – Chest X-ray 10 .....	26
Image L – Chest X-ray 11 .....	27
Image M – Chest X-ray 12 .....	28
Image N – Chest X-ray 13 .....	29
Image O – Chest X-ray 14 .....	30
Image P – Chest X-ray 15 .....	31
Image Q – Chest X-ray 16 .....	32

## List of tables

Table A – Technical Grading .....	14
Table B – Interpretation of chest X-ray 1.....	17
Table C – Interpretation of chest X-ray 2.....	18
Table D – Interpretation of chest X-ray 3 .....	19
Table E – Interpretation of chest X-ray 4.....	20
Table F – Interpretation of chest X-ray 5 .....	21
Table G – Interpretation of chest X-ray 6 .....	22
Table H – Interpretation of chest X-ray 7 .....	23
Table I – Interpretation of chest X-ray 8.....	24
Table J – Interpretation of chest X-ray 9.....	25
Table K – Interpretation of chest X-ray 10.....	26
Table L – Interpretation of chest X-ray 11 .....	27
Table M – Interpretation of chest X-ray 12 .....	28
Table N – Interpretation of chest X-ray 13 .....	29
Table O – Interpretation of chest X-ray 14 .....	30
Table P – Interpretation of chest X-ray 15.....	31
Table Q – Interpretation of chest X-ray 16.....	32

## Acknowledgement

The original standards and guidelines were developed in consultation with Australian and international experts in chest X-ray screening for pneumoconiosis and radiology including:

- Professor Robert Cohen MD, FCCP, B-Reader, Clinical Professor of Environmental and Occupational Health Sciences, University of Illinois Chicago School of Public Health
- Dr Katrina Newbiggin, FRANZCR, B-Reader
- Dr Nigel Sommerfeld, FRANZCR
- Dr Janet Gray, FRANZCR, State Radiologist, BreastScreen Queensland.

This updated version has been reviewed in consultation with the Resources Medical Advisory Committee (RMAC) including:

- Dr Catherine Jones, FRANZCR, B-Reader and RMAC member
- Professor Robert Cohen MD, FCCP, B-Reader, Clinical Professor of Environmental and Occupational Health Sciences, University of Illinois Chicago School of Public Health and RMAC member.

## Acronyms and abbreviations

ACPSEM	Australasian College of Physical Scientists and Engineers in Medicine
AHPRA	Australian Health Practitioner Regulation Agency
CWP	Coal workers' pneumoconiosis
CXR	Chest X-ray (radiograph)
DIAS	Diagnostic Imaging Accreditation Scheme
DICOM®	Digital Imaging and Communications in Medicine
DR	Digital radiography
ILO	International Labour Organization
NIOSH	National Institute for Occupational Safety and Health
PA	Posteroanterior
RANZCR	Royal Australian and New Zealand College of Radiologists

# Introduction

## 1. Background

The Coal Mine Workers' Health Scheme (the Scheme) aims to protect the health of Queensland coal mine workers by ensuring they undergo compulsory health assessments, with chest X-ray (CXR) examination a key component. Careful examination of high quality CXR images is crucial to detecting small opacities and other radiographic findings indicative of early dust lung diseases.<sup>1</sup>

In 2016, the Monash University Centre for Occupational and Environmental Health in collaboration with the School of Public Health at the University of Illinois at Chicago, reviewed the respiratory component of the Coal Mine Workers' Health Scheme (Monash review).<sup>2</sup> The Monash review recommended guidelines be provided to radiology practices performing CXR for the Scheme, detailing the appropriate qualification of personnel, imaging equipment and software, image acquisition, documentation, image display and quality control systems.<sup>3</sup>

This document was initially developed in response to the Monash review recommendation to provide standards based on the National Institute for Occupational Safety and Health (NIOSH) *Guideline for the Application of Digital Radiography for the Detection and Classification of Pneumoconiosis* adapted for use in Australia.<sup>4</sup>

This updated version incorporates technological advances and identified learnings from various audits, stakeholder feedback and updated standards. In addition, amendments to the Mining and Quarrying Safety and Health Regulation 2017, that commenced on 1 September 2020, also require Queensland mineral mine and quarry workers undertake respiratory health surveillance including a CXR performed in accordance with this standard and guideline.<sup>5</sup>

## 2. Purpose

This document has two parts. Part 1 details the standards for radiology practices and personnel involved in acquiring digital CXR images for mine and quarry workers. The objective of the

---

<sup>1</sup> Monash review p18.

<sup>2</sup> Monash review - [https://www.rshq.qld.gov.au/\\_data/assets/pdf\\_file/0009/383940/monash-qcwp-final-report-2016.pdf](https://www.rshq.qld.gov.au/_data/assets/pdf_file/0009/383940/monash-qcwp-final-report-2016.pdf)

<sup>3</sup> Refer to recommendation 11.5 of the Monash review.

<sup>4</sup> NIOSH Guideline - <https://www.cdc.gov/niosh/docs/2011-198/>

<sup>5</sup> Mining and Quarrying Safety and Health Regulation - [Mining and Quarrying Safety and Health Regulation 2017 - Queensland Legislation - Queensland Government](#)

standards is to identify requirements and highlight existing Australian standards that are considered important in generating high quality digital CXR images for the purpose of detecting pneumoconiosis.

Part 2 provides a guideline on use of the technical quality grading scale of CXR images under the updated International Labour Organization (ILO) *Guidelines for the use of the ILO International Classification of Radiographs of Pneumoconioses 2022* (ILO Classification).<sup>6</sup> All CXR images taken under the Scheme for coal mine workers or for respiratory health surveillance for mineral mine and quarry workers must be performed in accordance with the ILO Classification. The guideline in this document seeks to inform practices how CXR images are graded and the associated technical issues that can reduce image quality for the purposes of reporting images to the ILO Classification.

Draft

---

<sup>6</sup> ILO Classification 2022 - [https://www.ilo.org/global/topics/safety-and-health-at-work/areasofwork/occupational-health/WCMS\\_868501/lang-en/index.htm](https://www.ilo.org/global/topics/safety-and-health-at-work/areasofwork/occupational-health/WCMS_868501/lang-en/index.htm)



# Part 1: Standards

## 1. Government regulation

- 1.1 Radiology practices involved in acquiring digital CXR images for mine and quarry workers are required to comply with all relevant State or Territory and Commonwealth legislation.

## 2. RANZCR and DIAS standards

Radiology practices and the personnel involved in acquiring digital CXR images for mine and quarry workers are required to:

- 2.1 Comply with the Royal Australian and New Zealand College of Radiologists' (RANZCR) *Standards of Practice for Clinical Radiology*.<sup>7</sup>
- 2.2 Be accredited with the Diagnostic Imaging Accreditation Scheme (DIAS).<sup>8</sup>
- 2.3 Comply with the *DIAS Standards*.<sup>9</sup>

## 3. Personnel

### Medical physicists

Medical physicists involved in diagnostic imaging services for mine and quarry workers, including auditing and servicing systems and equipment, shall meet the following requirements:

- 3.1 Registered on the Australasian College of Physical Scientists and Engineers in Medicine (ACPSEM) Register of Qualified Medical Physics Specialists in the Radiology Medical Physics Specialty.<sup>10</sup>
- 3.2 Licenced by the relevant State or Territory radiation regulator to use radiation apparatus in their capacity as medical physicists.

---

<sup>7</sup> RANZCR Standards of Practice - <https://www.ranzcr.com/college/document-library/standards-of-practice-for-clinical-radiology>

<sup>8</sup> DIAS accreditation - <https://www.safetyandquality.gov.au/standards/diagnostic-imaging/diagnostic-imaging-accreditation-scheme>

<sup>9</sup> DIAS Practice Accreditation Standards - <https://www.safetyandquality.gov.au/standards/diagnostic-imaging/diagnostic-imaging-accreditation-scheme-standards>

<sup>10</sup> The ACPSEM Register - <https://www.acpsem.org.au/ACPSEM-Register>

## Radiographers

Radiographers acquiring digital CXR images for mine and quarry workers shall meet the following requirements:

- 3.3 Registered as a medical radiation practitioner with the Australian Health Practitioner Regulation Agency (AHPRA).
- 3.4 Possess a current radiation use licence for the State or Territory within which the radiographer practices.

## 4. Imaging equipment and software

- 4.1 Medical imaging clinics providing services to mine and quarry workers shall ensure its equipment and software meet the requirements below in addition to the *RANZCR Standards of Practice* and the *DIAS Standards*.

### Imaging equipment

- 4.2 Only digital radiography (DR) imaging equipment to be used.
- 4.3 The equipment should be installed and used in accordance with the manufacturer's specifications.
- 4.4 Where available, and in consultation with the application specialist, the manufacturer's imaging equipment specific ILO protocol should be used.
- 4.5 Equipment should meet testing as required by State or Territory radiation licencing.

### Image capture hardware and software

- 4.6 Spatial resolution should be at least 2.5 line pairs per mm in both vertical and horizontal directions measured at the image receptor.
- 4.7 Detectors must undergo routine cleaning and quality assurance as recommended by the manufacturer and in accordance with the RANZCR General X-ray QA and QC Guideline<sup>11</sup>.
- 4.8 Detector signals must undergo routine amplification if required as well as standard image post processing.
- 4.9 two images can be used if they include all lung fields, both apices and costophrenic angles.

---

<sup>11</sup> RANZCR *General X-ray QA and QC Guideline* - <https://www.ranzcr.com/college/document-library/general-x-ray-quality-assurance-and-quality-control-guidelines>

## Image manipulation

- 4.10 Image management software and settings for routine chest imaging supplied by the image processing vendor must be used.
- 4.11 Image or edge enhancement functions **must not** be used, or associated settings set to lowest possible on the imaging equipment.

## Image data file

- 4.12 Image data file and associated transmission and storage must be in line with the DICOM® standard.
- 4.13 If data compression is performed, it must be lossless.
- 4.14 Data systems must have sufficient physical, technical, and administrative controls to prevent unauthorised access to health data.

## 5. Image acquisition

- 5.1 Images must be taken digitally at the source.

### Beam limiting devices

- 5.2 Radiographic equipment must have a beam-limiting device used with the radiographic image examination, which does not cause unexposed boundaries.
- 5.3 Post-image acquisitions such as “shutters” which simulate collimator limits and limit the size of the final image **must not** be used.

### Equipment specifications

- 5.4 The distance from source or focal spot to digital detector should be at least 180cm.
- 5.5 The maximum exposure time should be as low as possible within patient and equipment manufacturer parameters.
- 5.6 The minimum voltage recommended by the digital imaging system manufacturer should be used for chest radiography, preferably using high kV technique (up to 125kVp) and at least 90kVp while minimising radiation exposure.
- 5.7 Where available, adhere to equipment manufacturer’s settings and guidelines on exposure for a standard PA chest radiograph.
- 5.8 A suitable grid (e.g. with a ratio of 12:1 or 14:1) is recommended for reducing scattered radiation in accordance with equipment manufacturer’s guidelines; however special caution is advised in the selection of grids for use with digital systems so that image artefacts do not occur.

- 5.9 Equipment should be maintained to the equipment manufacturer's specifications as per DIAS requirements and inspected in accordance with State or Territory regulations.

### **Image quality**

- 5.10 The practice must have evidence of a documented and reviewed chest imaging protocol approved by the lead radiologist, lead radiographer and/or medical physicist.
- 5.11 Radiographers should work to the RANZCR General X-ray QA and QC Guideline and chest imaging protocols for ILO classification, including ensuring correct patient identification and procedure matching, and removal of external artefacts to ensure CXR image quality is acceptable.
- 5.12 Before the subject is advised that the examination is concluded, the CXR image should be processed to an image file and inspected and accepted for quality by a radiologist or radiographer.
- 5.13 The practice must have evidence of ongoing image quality review, with appropriate action taken to implement and maintain continuous improvement.
- 5.14 CXR images should be ILO quality 1 or 2, as determined in the single final ILO Classification report, that has included the CXR image being read by at least two NIOSH certified B-Readers. Fewer than 5 per cent of CXR images should be graded technical quality 3 or 4 (refer to Part 2 for grading).

## **6. Documentation**

- 2.1 Images must be stored as DICOM<sup>®</sup> Digital X-ray (DX) objects.<sup>12</sup>
- 2.2 Identification of the image, patient, facility, date and time of the examination must be included in the file header according to the DICOM<sup>®</sup> standard format.
- 2.3 For auditing purposes, the radiographer responsible for performing the CXR must note the exposure parameters (kVp, mA, time) and where possible, the beam filtration, scatter reduction and radiation exposure, on the image (or saved within the DICOM<sup>®</sup> file).

---

<sup>12</sup> Medical Imaging and Technology Alliance *Digital Imaging and Communications in Medicine (DICOM<sup>®</sup>) Standard*  
<https://www.dicomstandard.org/current/>

## 7. Quality assurance and control

- 3.1 The practice must implement a radiation Safety and Protection Plan or equivalent Radiation Management Plan as required by State or Territory licensing to ensure radiation dose is minimised.
- 3.2 Quality assurance testing must be performed periodically as recommended by the equipment manufacturers and suppliers and the results documented.
- 3.3 Additionally, quality control is to be carried out according to the RANZCR General X-ray QA and QC Guideline, except with the frequencies indicated in the RANZCR Guidelines for Quality Control Testing for Digital (CR DR) Mammography<sup>13</sup> where there is an equivalent test.

---

<sup>13</sup> RANZCR Guidelines for Quality Control Testing for Digital (CR DR) Mammography, <https://www.ranzcr.com/fellows/clinical-radiology/quality-assurance-and-accreditation/mgap>.

## Part 2: Technical guidelines for X-ray image quality assessment for ILO classification

The ILO Classification describes the process for systematically describing and recording radiographic abnormalities of the chest.. In addition, the ILO classification system also considers technical quality of CXR images, with an adequate view of the pulmonary parenchyma and pleura, to ensure they are acceptable for accurate classification purposes.

### 1. Technical quality grading of images

The ILO Classification grades CXR image quality from 1 to 4 with grade 1 images being the highest quality. An explanation of the grading is provided below.

**Table A – Technical Grading**

ILO grading <sup>14</sup>	Technical explanation
<b>Grade 1:</b> Good. Free of technical imperfections	-
<b>Grade 2:</b> Acceptable. Minor technical imperfections that do not impair classification for pneumoconiosis.	<ul style="list-style-type: none"><li>• Minor artefacts that are not projected over the heart or lungs</li></ul>
<b>Grade 3:</b> Acceptable, with some technical defects or artefacts but still able to classify.	<ul style="list-style-type: none"><li>• Minor under or over exposure that does not preclude assessment of opacities</li><li>• Minor blurring or motion</li><li>• Malposition that does not preclude assessment</li></ul>
<b>Grade 4:</b> Unacceptable for classification purposes	<ul style="list-style-type: none"><li>• Incomplete imaging of the lungs</li><li>• Malposition which precludes assessment</li><li>• Marked under or over exposure</li><li>• Unable to grade</li></ul>

If an image is not graded 1, a comment must be made about the technical defect on the ILO Classification form as shown in Image A. As part of the ongoing image quality review, these

---

<sup>14</sup> ILO Classification 2022 - [https://www.ilo.org/global/topics/safety-and-health-at-work/areasofwork/occupational-health/WCMS\\_868501/lang--en/index.htm](https://www.ilo.org/global/topics/safety-and-health-at-work/areasofwork/occupational-health/WCMS_868501/lang--en/index.htm)

comments should be reviewed and implementing an appropriate quality improvement to image acquisition is important to maintain high levels of image quality.

### Image A – ILO Classification form Section 1

1. IMAGE QUALITY				<input checked="" type="checkbox"/> Overexposed (dark)	<input type="checkbox"/> Improper position	<input type="checkbox"/> Underinflation	<input checked="" type="checkbox"/> Scapula Overlay
<input type="checkbox"/> 1	<input checked="" type="checkbox"/> 2	<input type="checkbox"/> 3	<input type="checkbox"/> 4	<input type="checkbox"/> Underexposed (light)	<input type="checkbox"/> Poor contrast	<input type="checkbox"/> Mottle	<input type="checkbox"/> Other (please specify)
(If not grade 1, mark all boxes that apply)				<input type="checkbox"/> Artifacts	<input type="checkbox"/> Poor processing	<input type="checkbox"/> Excessive Edge Enhancement	_____

## 2. Common difficulties

The most common causes of a less than quality 1 image include scapula overlay, excessive or inadequate exposure, excessive edge enhancement and thick soft tissue over the chest wall.

### Improper position including scapula overlay

Many mine and quarry workers have rotator cuff issues or back problems and cannot completely rotate their scapula off the chest. Radiographers should assist the worker to permit as much rotation of the scapula as possible. The radiographer should use the radiology information system to report any difficulties encountered in acquiring an adequate image to the clinical radiologist.

### Excessive edge enhancement

Edge enhancement may artificially create the appearance of small opacities and should not be used, or reduced to the lowest setting when the equipment does not have a zero setting.

### Thick chest wall soft tissue

A thick chest wall caused by dense breast tissue, fat, or muscle can result in reduced contrast penetration in the lower lobes compared to the upper lobes, making it difficult to evaluate lower lobe small opacities. Proper attention to proper exposure must be ensured.

### Poor contrast

There can also be difficulty in distinguishing soft tissue contrast due to technical factors such as suboptimal exposure, and/or patient parameters such as chest wall soft tissue.

## **Mottle**

Digital 'Noise' on a CXR image resulting from fluctuations in the number of photons reaching the detector. This has an undesirable effect on CXR image quality, particularly when performed using low radiation doses. Mottle is more likely when imaging patients with a larger body mass, and adjustments should be made accordingly when acquiring such CXR images.

## **Exposure (under or over exposure)**

Both over- and under-exposure can make it difficult to see all the information required for a diagnosis, resulting in an image that is either 'burnt out' and overly dark, or an overly white or light CXR image, respectively. Over-exposure can occur when the x-ray beam was too powerful, resulting in an excessive number of photons reaching the detector. Conversely, under-exposure can occur when the beam is not of sufficient strength to penetrate the patient's tissue.

Underexposure may result in incorrectly classifying an image as higher profusion when compared to optimally acquired radiographs. Conversely, overexposure may result in incorrectly classifying an image as lower profusion of opacities and reticulations.



### 3. Examples of images and interpretation

Image B – Chest X-ray 1

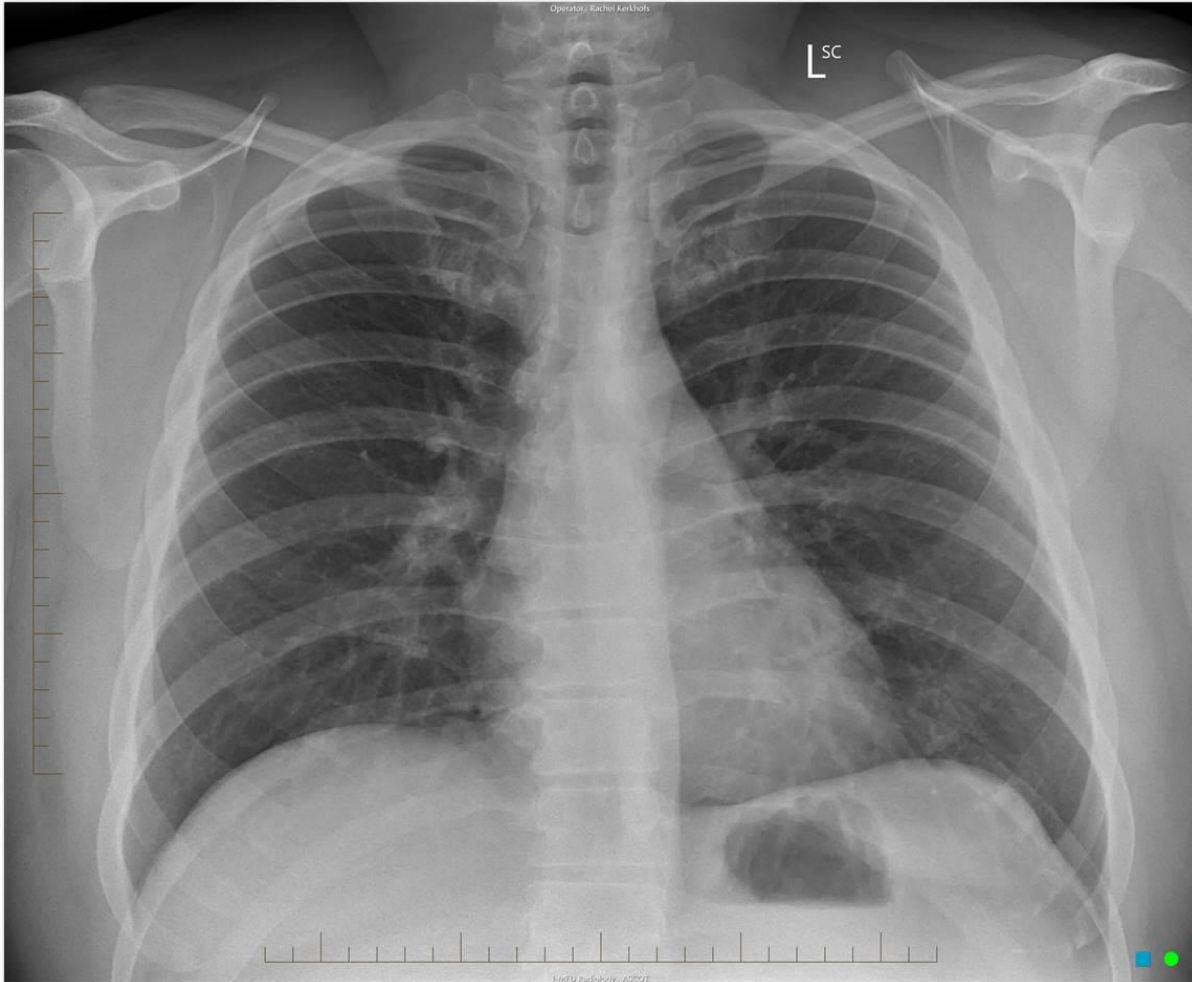


Table B – Interpretation of chest X-ray 1

<b>Grading</b>	1
<b>Interpretation</b>	<ul style="list-style-type: none"><li>• Good penetration</li><li>• Outline of both hemidiaphragms seen</li><li>• No scapular overlay across the lungs</li><li>• No edge enhancement</li></ul>

Image C – Chest X-ray 2

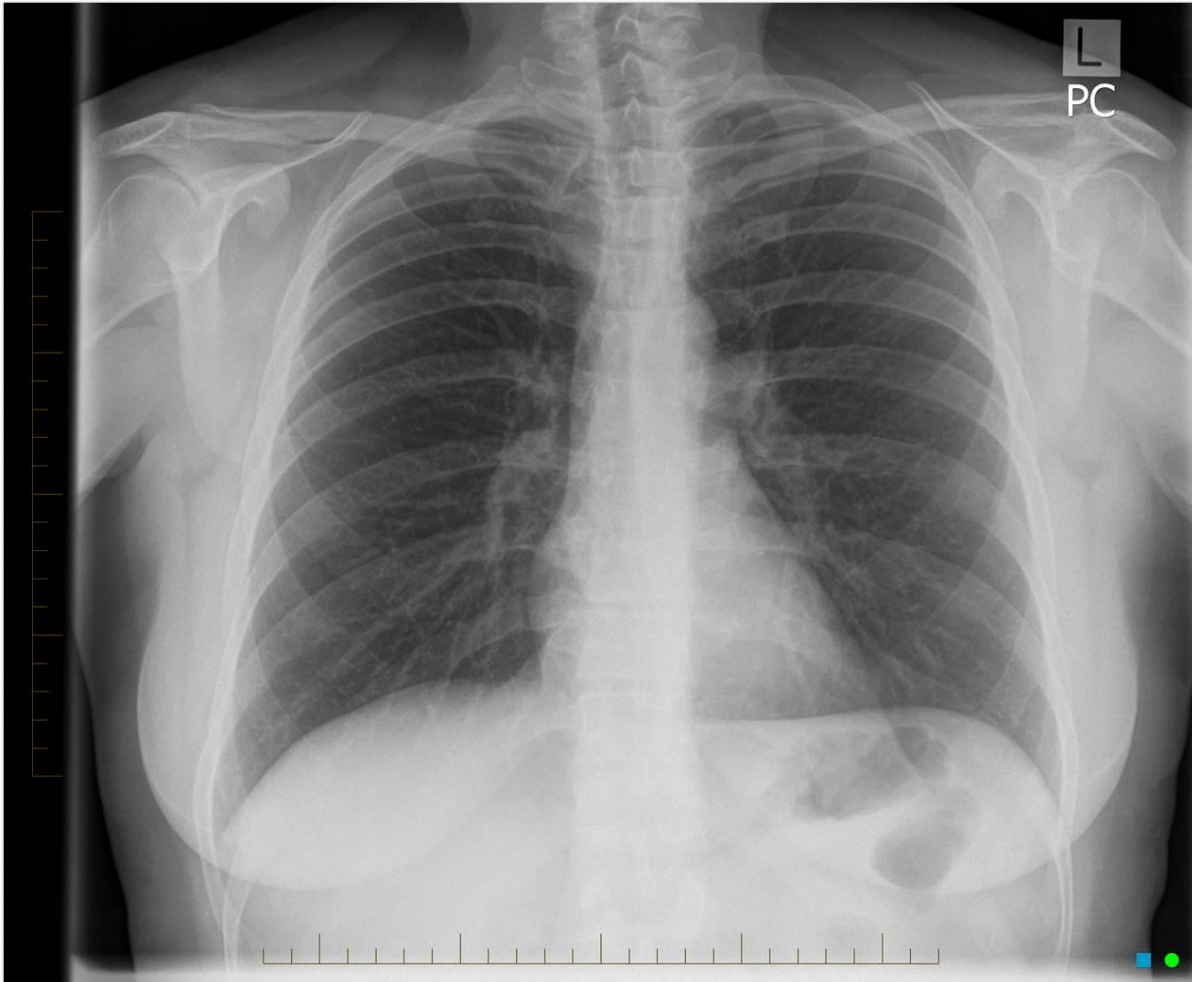


Table C – Interpretation of chest X-ray 2

<b>Grading</b>	1
<b>Interpretation</b>	<ul style="list-style-type: none"><li>• Good penetration</li><li>• No scapular overlay across the lungs</li><li>• No edge enhancement</li></ul>

Image D – Chest X-ray 3

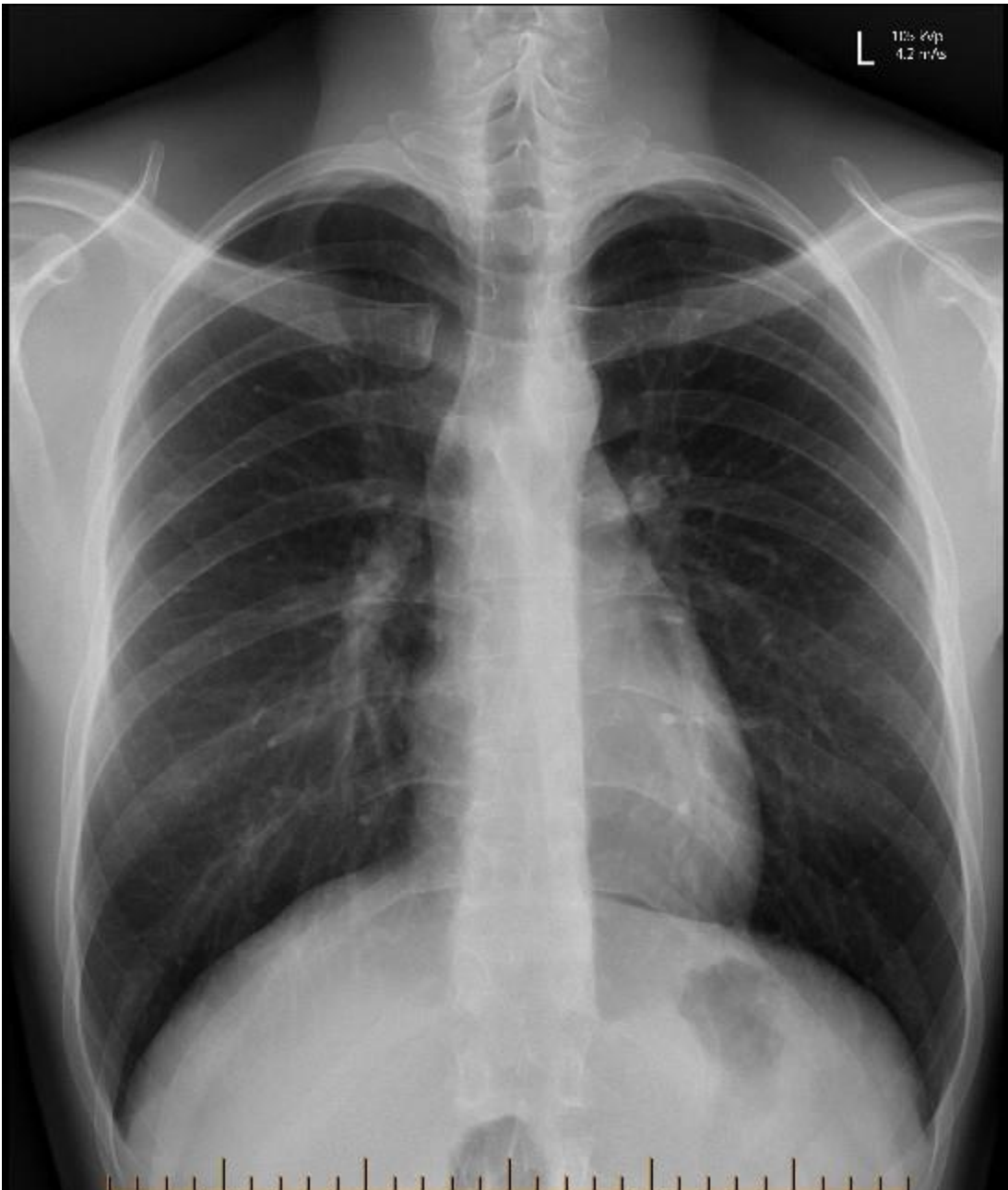


Table D – Interpretation of chest X-ray 3

<b>Grading</b>	2
<b>Interpretation</b>	<ul style="list-style-type: none"><li>• Improper position</li></ul>
<b>Note</b>	<ul style="list-style-type: none"><li>• The patient is rotated towards the right. The lung and pleural tissues however are well visualised.</li></ul>

Image E – Chest X-ray 4

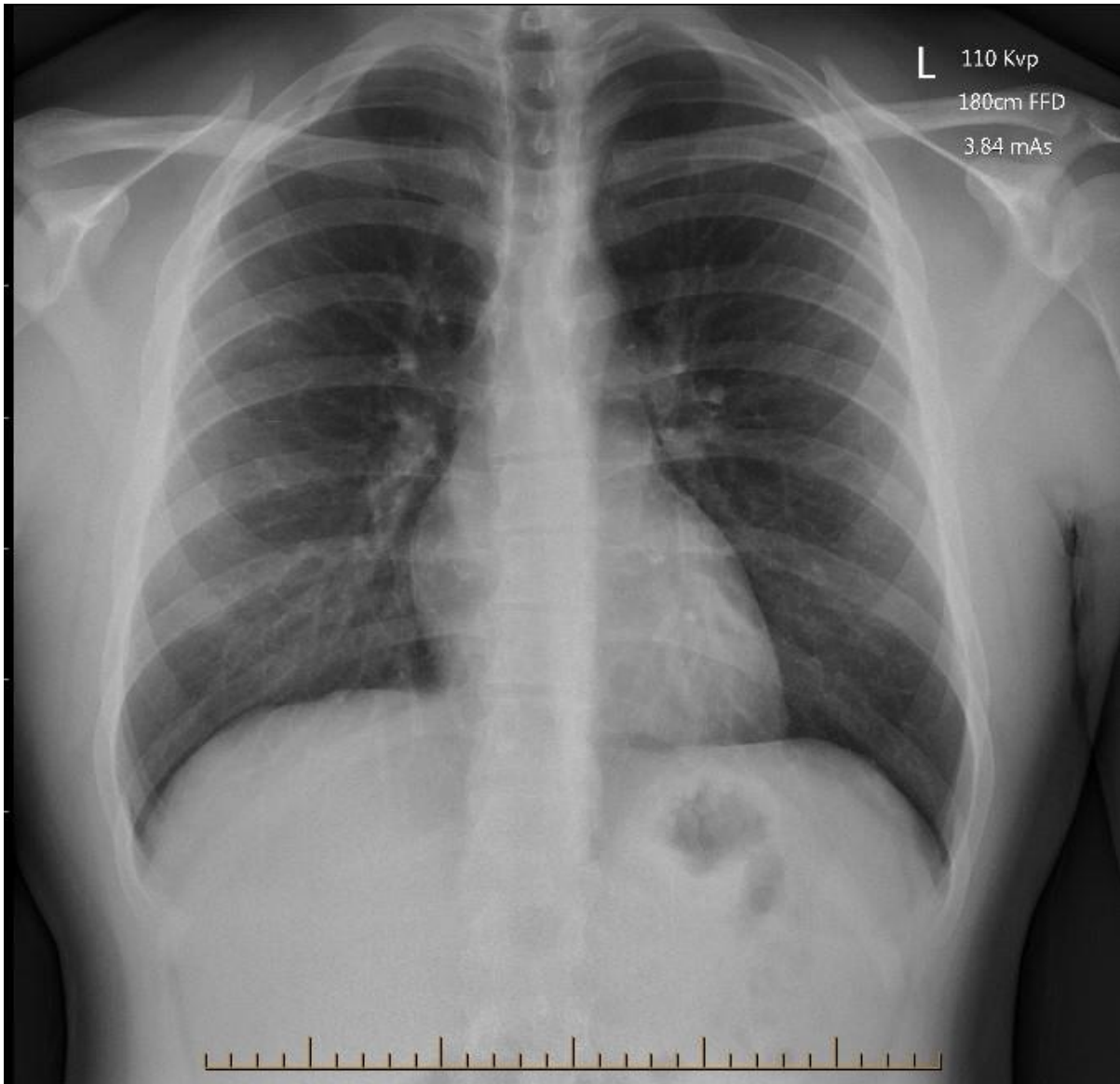
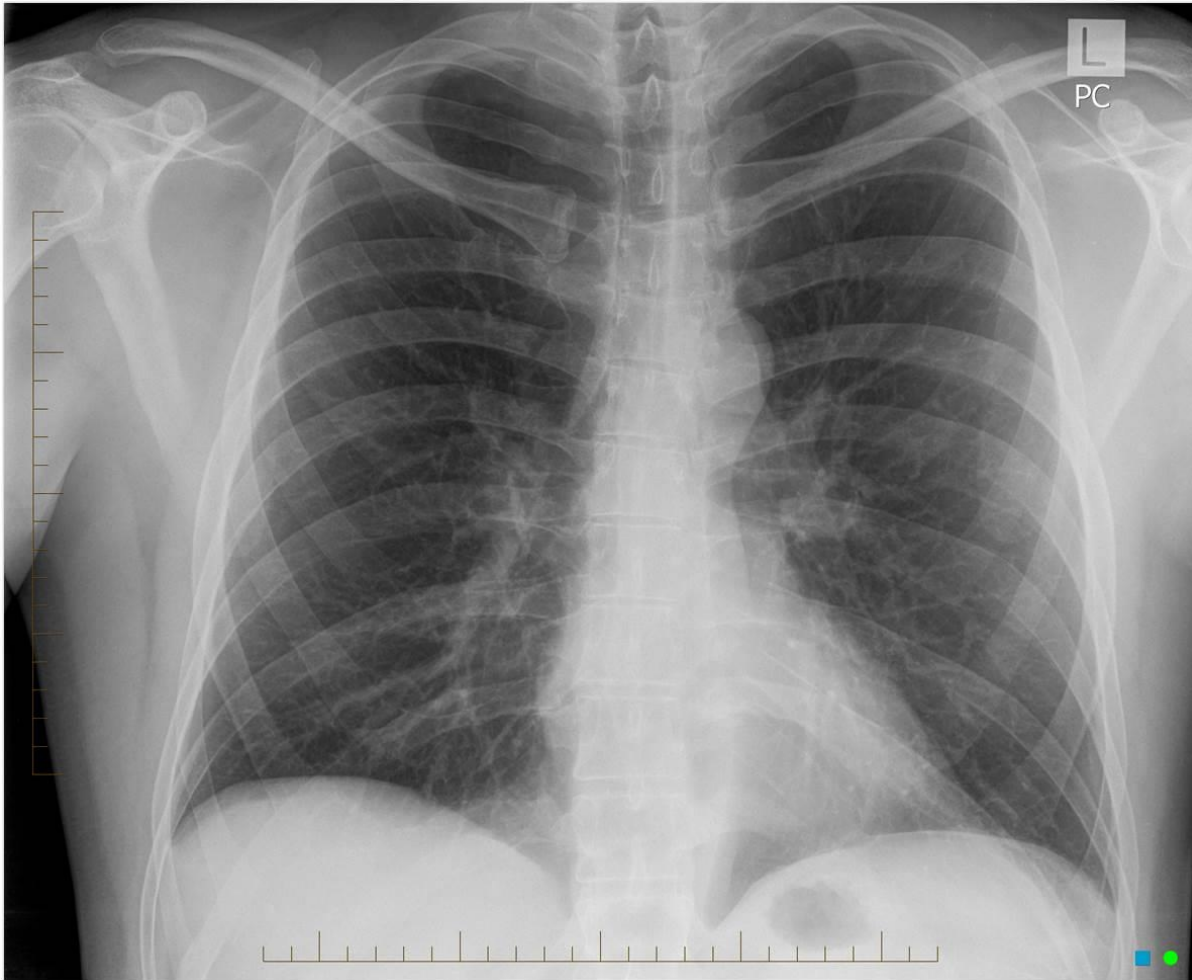


Table E – Interpretation of chest X-ray 4

<b>Grading</b>	2
<b>Interpretation</b>	<ul style="list-style-type: none"><li>• Improper position</li></ul>
<b>Note</b>	<ul style="list-style-type: none"><li>• The scapulae bilaterally are projected over the lateral edges of the lung fields. This is a common finding, and the patient may not be able to position their scapulae away from the lung tissues.</li><li>• Radiographers however should endeavour to position the patient as best as possible to avoid scapular overlay.</li></ul>

**Image F – Chest X-ray 5**



**Table F – Interpretation of chest X-ray 5**

<b>Grading</b>	2
<b>Interpretation</b>	<ul style="list-style-type: none"><li>• Improper position</li><li>• Minor scapula overlay</li></ul>
<b>Note</b>	<ul style="list-style-type: none"><li>• Patient rotation predisposes to scapular overlay</li></ul>



Image G – Chest X-ray 6

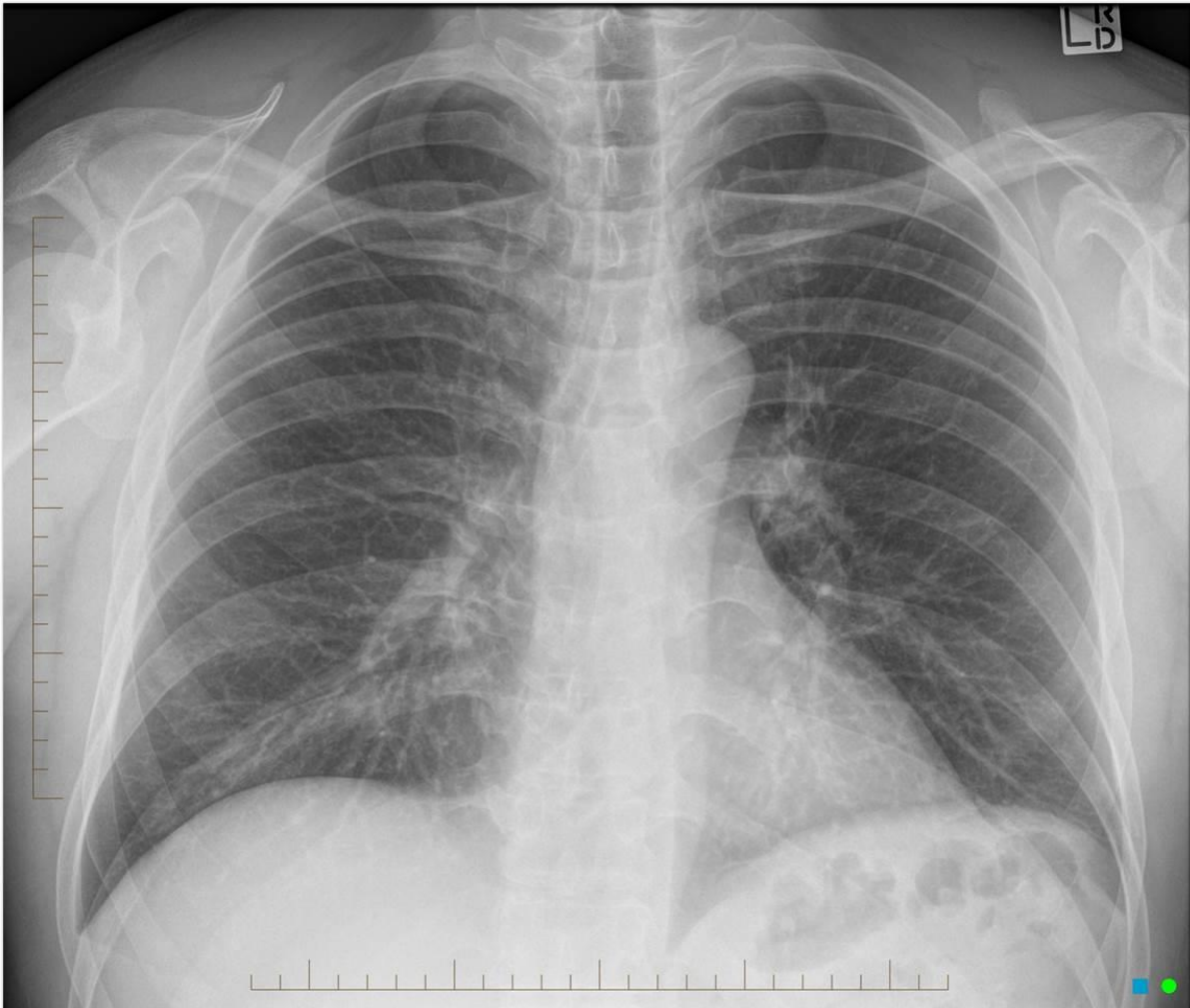
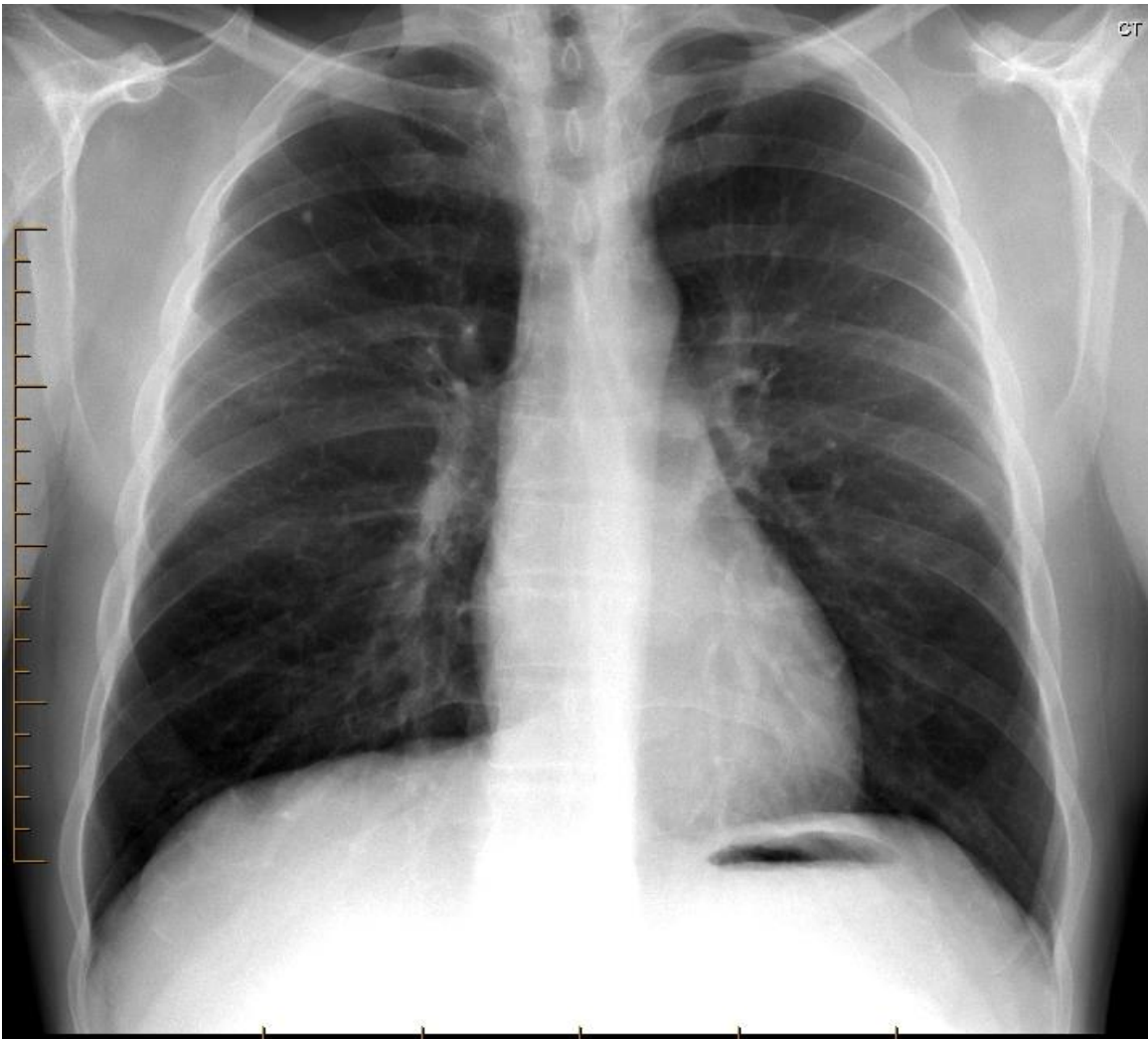


Table G – Interpretation of chest X-ray 6

<b>Grading</b>	2
<b>Interpretation</b>	<ul style="list-style-type: none"><li>• Excessive edge enhancement</li><li>• End on vessels stand out too much</li><li>• Easy to overcall as opacities</li></ul>

**Image H – Chest X-ray 7**



**Table H – Interpretation of chest X-ray 7**

<b>Grading</b>	2
<b>Interpretation</b>	<ul style="list-style-type: none"><li>• Overexposure</li></ul>
<b>Note</b>	<ul style="list-style-type: none"><li>• The excessive x-ray exposure setting has resulted in the image appearing dark and saturated with lung tissues poorly assessable.</li></ul>

Image I – Chest X-ray 8

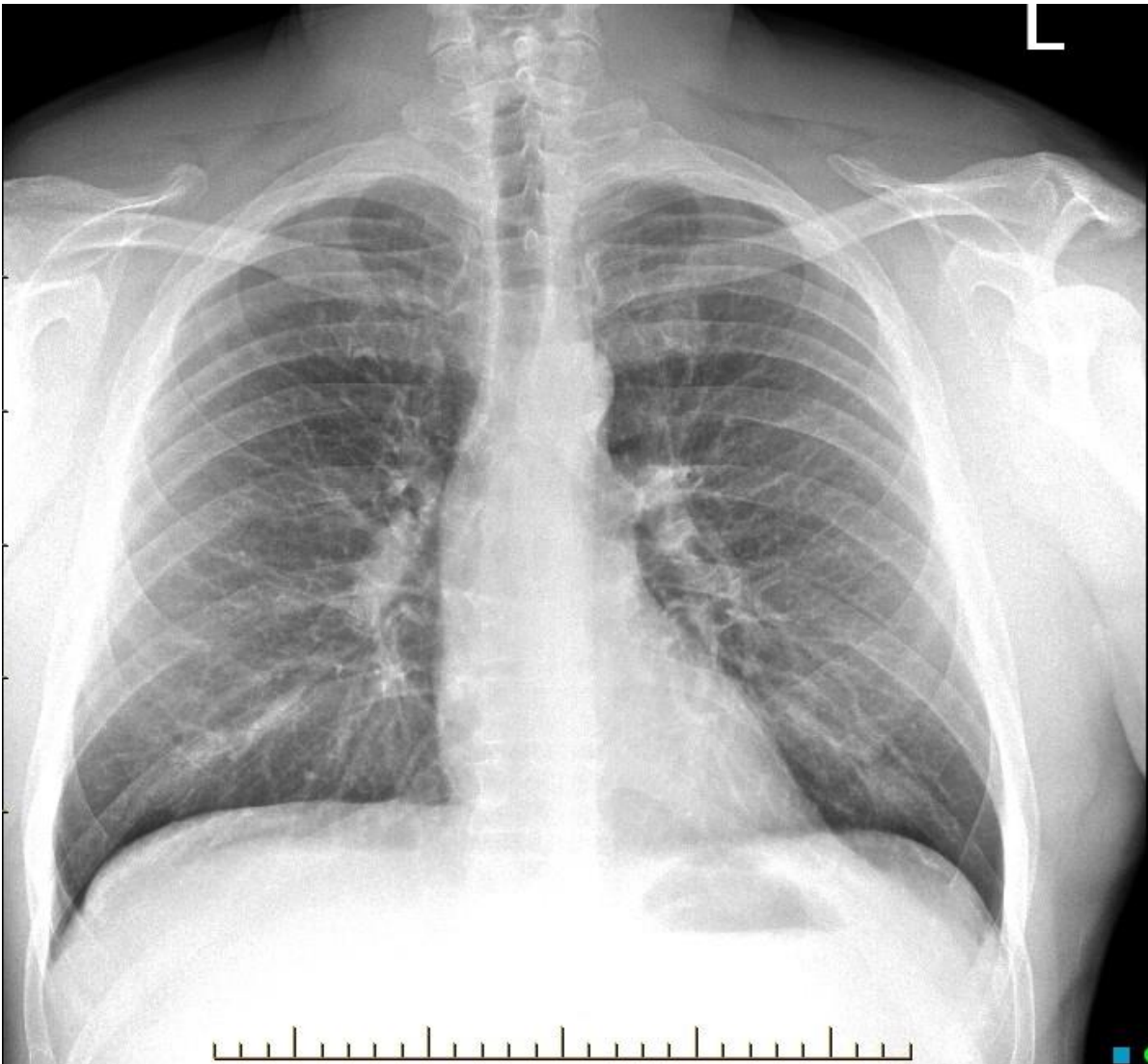


Table I – Interpretation of chest X-ray 8

<b>Grading</b>	3
<b>Interpretation</b>	<ul style="list-style-type: none"><li>• Mottle</li><li>• Underexposure</li></ul>
<b>Note</b>	<ul style="list-style-type: none"><li>• The soft tissues of the neck and chest wall are 'grainy' due to image noise (mottle).</li><li>• The lower thoracic spine and intervertebral spaces are not visible at all, and higher density structures are brighter than expected due to underexposure.</li></ul>



Image J – Chest X-ray 9

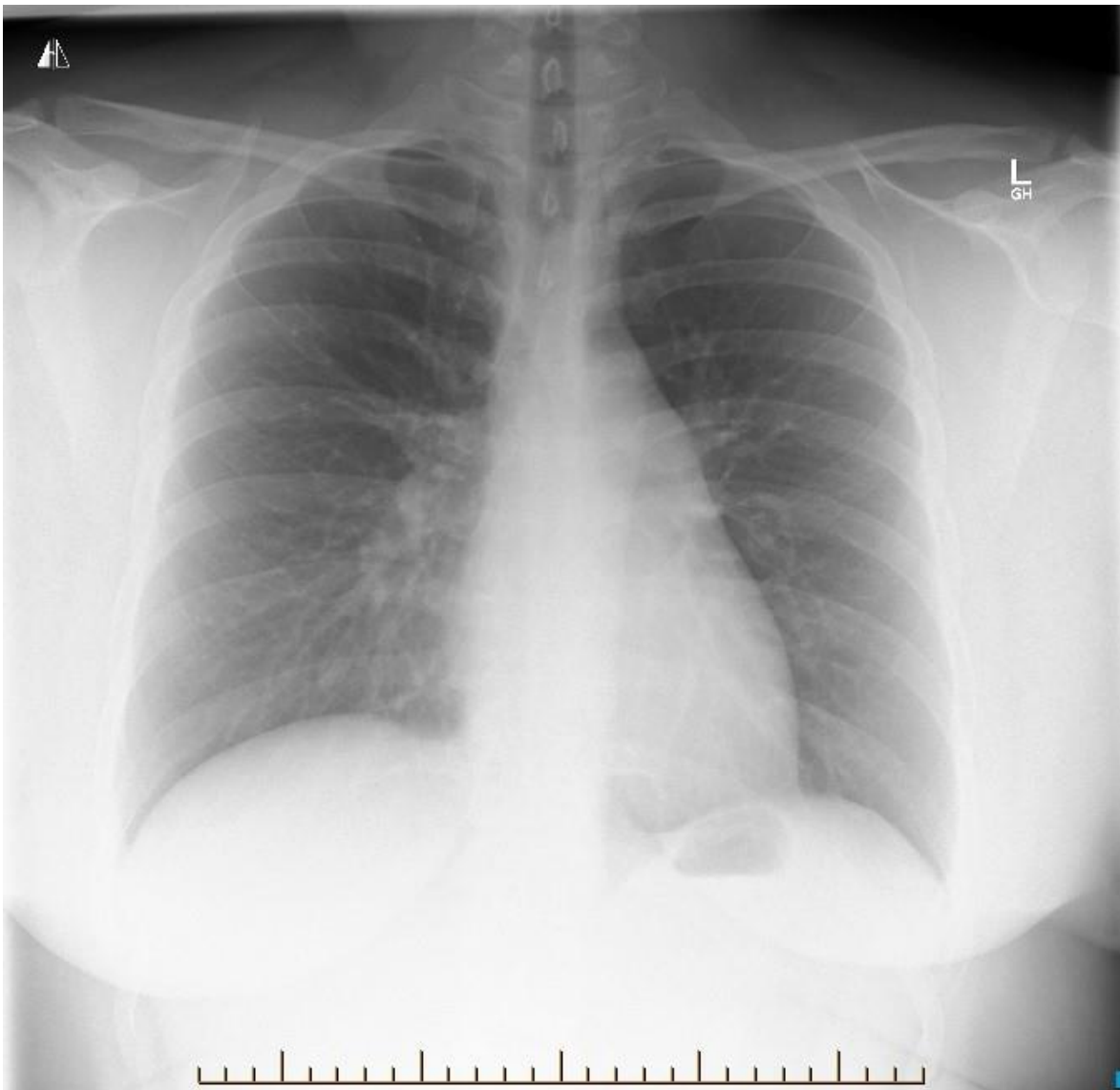


Table J – Interpretation of chest X-ray 9

<b>Grading</b>	3
<b>Interpretation</b>	<ul style="list-style-type: none"><li>• Underexposure, especially in lower lobes due to increased chest wall thickness.</li></ul>
<b>Note</b>	<ul style="list-style-type: none"><li>• This CXR shows insufficient x-ray penetration, which could not be corrected digitally after image processing.</li></ul>

Image K – Chest X-ray 10

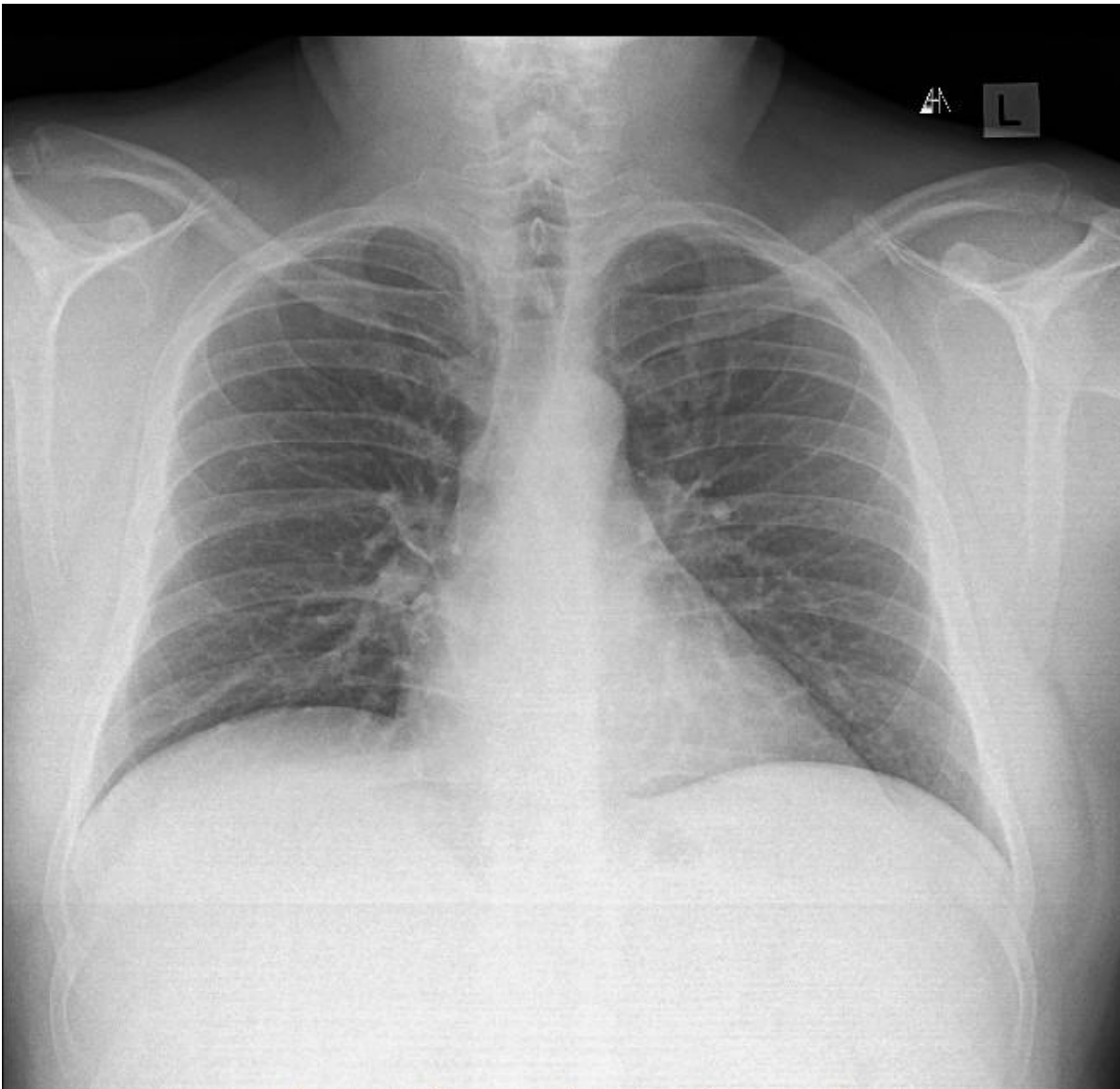
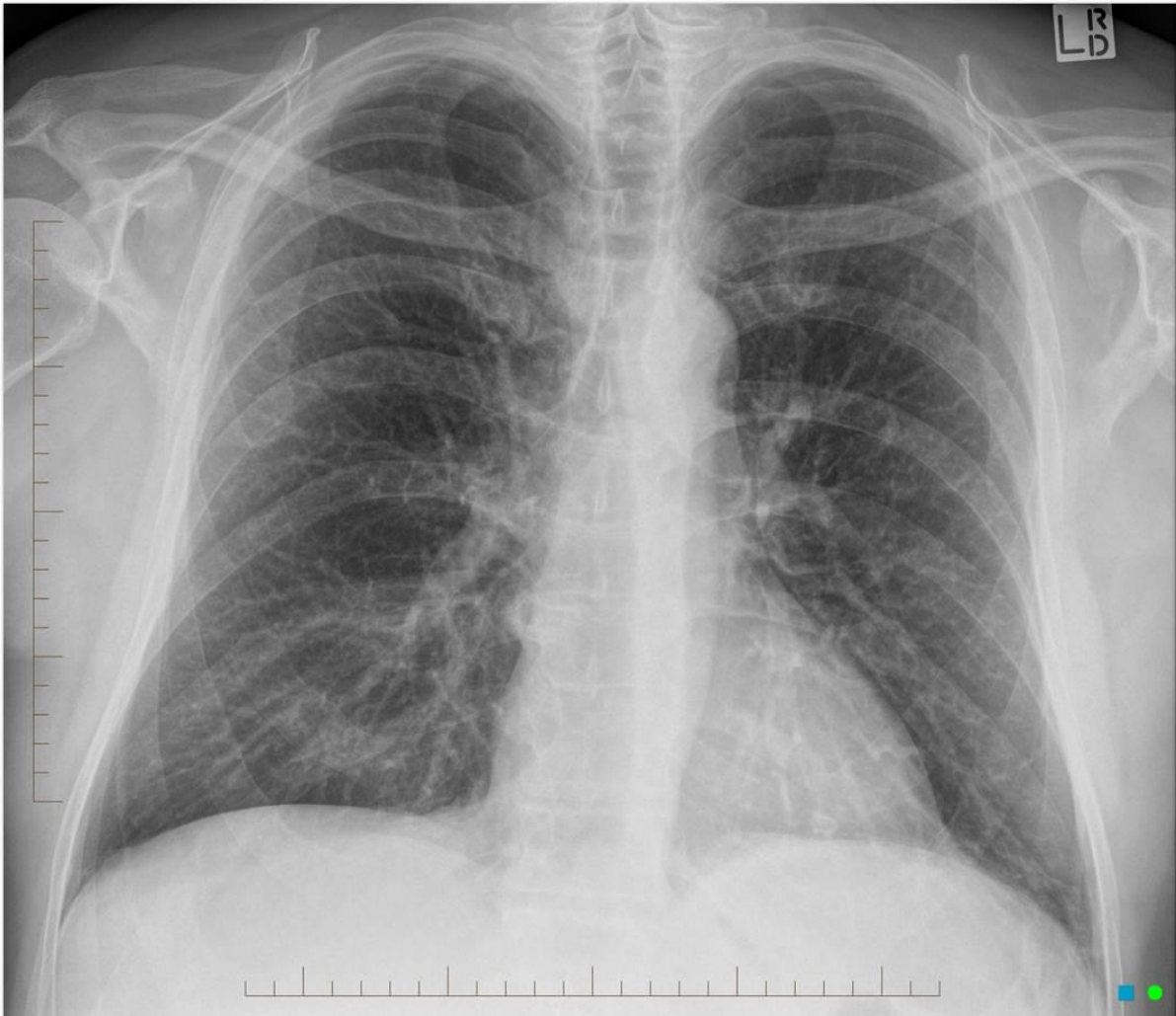


Table K – Interpretation of chest X-ray 10

<b>Grading</b>	3
<b>Interpretation</b>	Artefact
<b>Note</b>	Transverse linear aliasing artefacts suggestive of suboptimal grid settings. The lung structures are less affected than the soft tissues in this example.

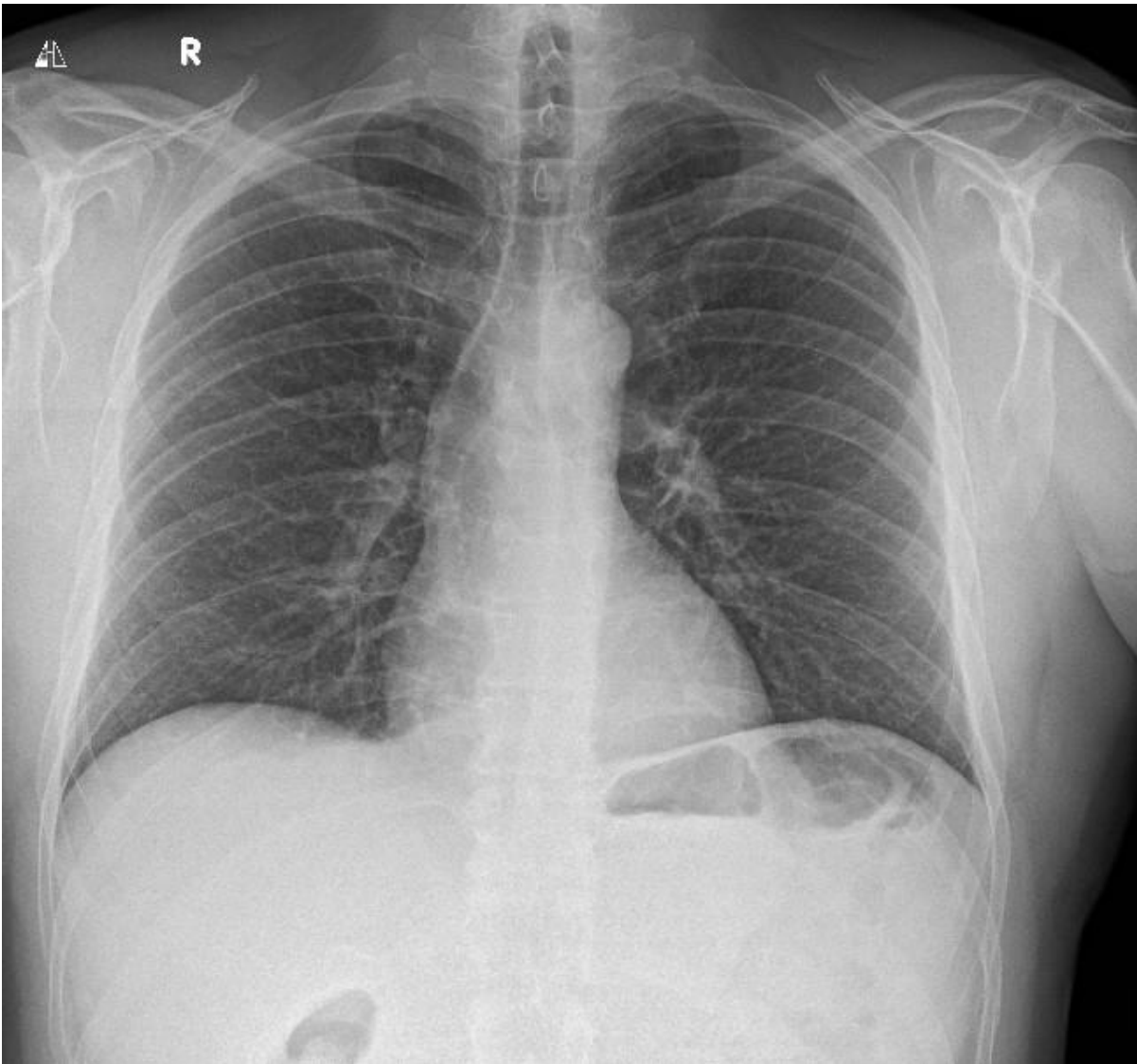
**Image L – Chest X-ray 11**



**Table L – Interpretation of chest X-ray 11**

<b>Grading</b>	3
<b>Interpretation</b>	<ul style="list-style-type: none"><li>• Improper position</li><li>• Poor contrast</li><li>• Excessive edge enhancement and scapula overlay</li></ul>
<b>Note</b>	<ul style="list-style-type: none"><li>• Consider repeat</li></ul>

**Image M – Chest X-ray 12**



**Table M – Interpretation of chest X-ray 12**

<b>Grading</b>	3
<b>Interpretation</b>	Suboptimal edge enhancement
<b>Note</b>	Post processing of the digital image producing sharp edges between the aerated lung and the lung vessels/airways. Subtle reticulations and nodules are difficult to exclude due to these technical factors.

Image N – Chest X-ray 13

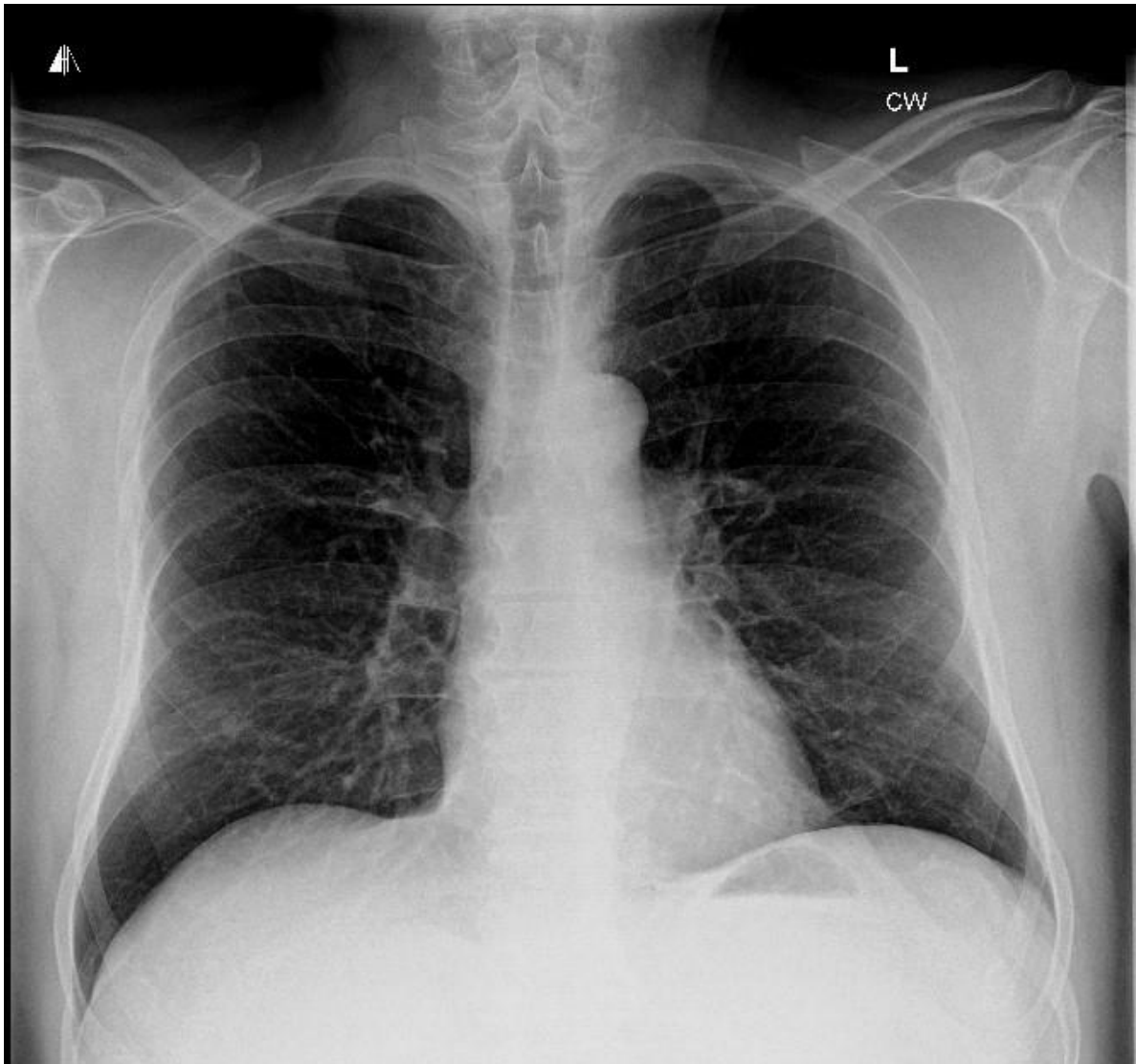
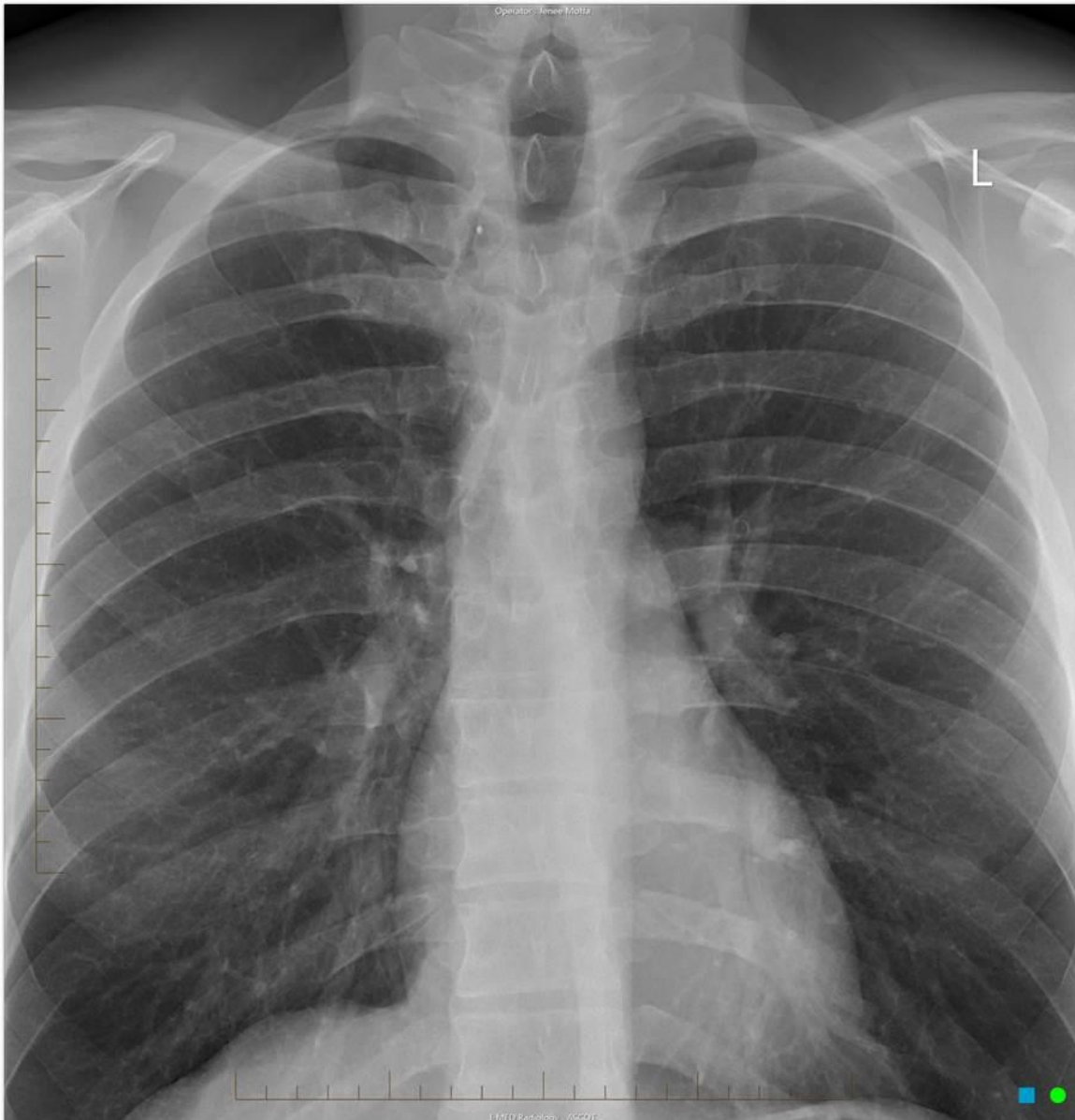


Table N – Interpretation of chest X-ray 13

<b>Grading</b>	4
<b>Interpretation</b>	<ul style="list-style-type: none"><li>• Suboptimal edge enhancement</li><li>• Overexposure</li></ul>
<b>Note</b>	<ul style="list-style-type: none"><li>• This CXR shows both suboptimal edge enhancement (producing an overly sharp edge between aerated lung tissue and normal vessels/airways) and an overexposed image (producing a dark, saturated appearance in the lung fields which cannot be corrected digitally).</li></ul>



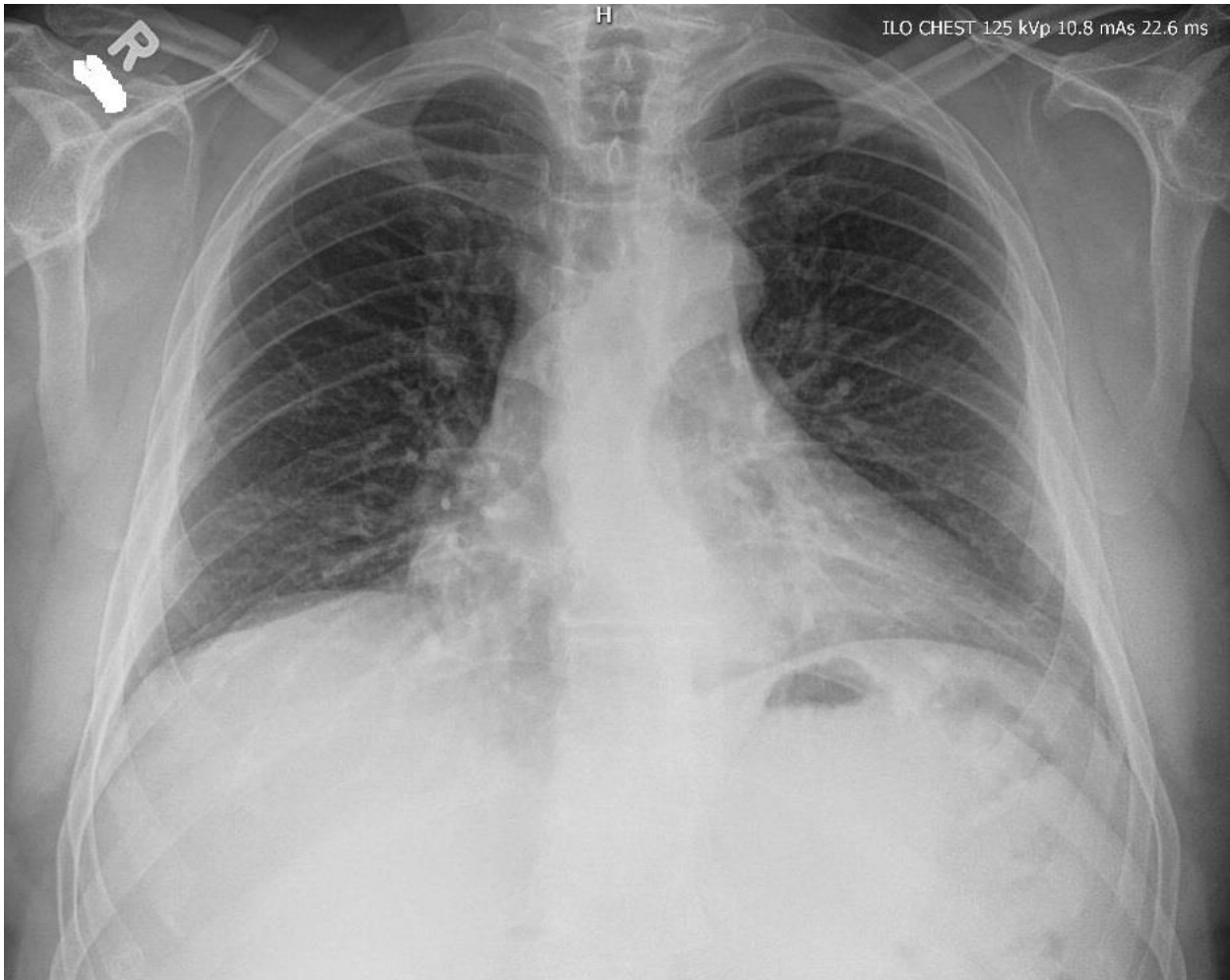
**Image O – Chest X-ray 14**



**Table O – Interpretation of chest X-ray 14**

<b>Grading</b>	4
<b>Interpretation</b>	<ul style="list-style-type: none"><li>• Improper positioning</li><li>• Costophrenic angles and lateral chest cut off</li></ul>
<b>Note</b>	<ul style="list-style-type: none"><li>• Repeat</li></ul>

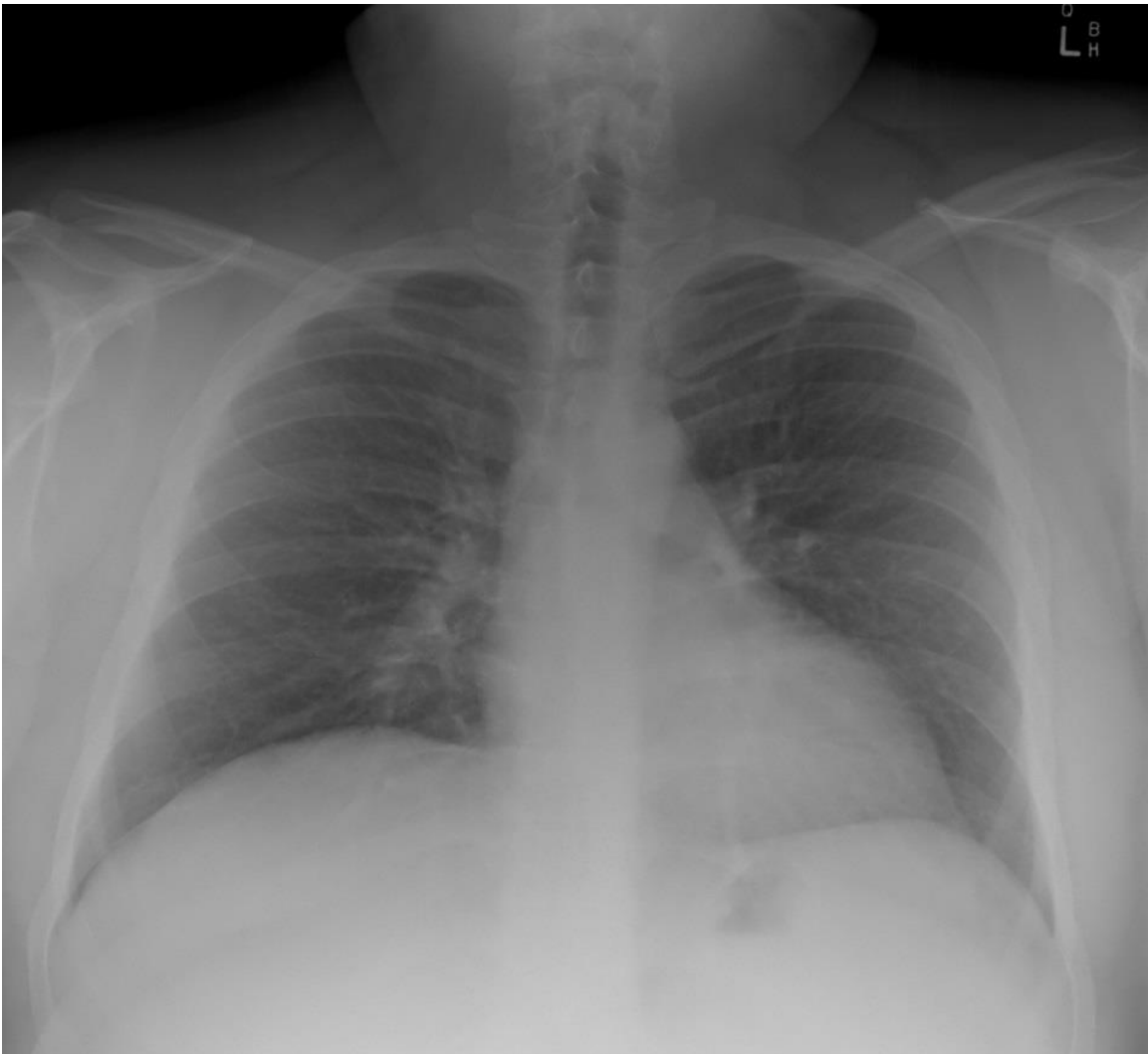
**Image P – Chest X-ray 15**



**Table P – Interpretation of chest X-ray 15**

<b>Grading</b>	4
<b>Interpretation</b>	<ul style="list-style-type: none"><li>• Underinflation</li><li>• Mottle</li></ul>

**Image Q – Chest X-ray 16**



**Table Q – Interpretation of chest X-ray 16**

<b>Grading</b>	4
<b>Interpretation</b>	<ul style="list-style-type: none"><li>• Underexposed</li><li>• Underinflation</li></ul>



## References

1. Monash University and the University of Illinois at Chicago. (2016, July 12). *Review of the Respiratory Component of the Coal Mine Workers' Health Scheme for the Queensland Department of Natural Resources and Mines Final Report*. Retrieved 30 May, 2023, from [https://www.rshq.qld.gov.au/\\_data/assets/pdf\\_file/0009/383940/monash-qcwp-final-report-2016.pdf](https://www.rshq.qld.gov.au/_data/assets/pdf_file/0009/383940/monash-qcwp-final-report-2016.pdf)
2. National Institute for Occupational Safety and Health. (2011, August). *NIOSH Guideline Application of Digital Radiography for the Detection and Classification of Pneumoconiosis*. Retrieved 30 May, 2023, from <https://www.cdc.gov/niosh/docs/2011-198/default.html>
3. International Labour Organization. (2022). *Guidelines for the use of the ILO International Classification of Radiographs of Pneumoconioses Revised edition 2022*. Retrieved May 30, 2023, from [https://www.ilo.org/global/topics/safety-and-health-at-work/areasofwork/occupational-health/WCMS\\_868501/lang-en/index.htm](https://www.ilo.org/global/topics/safety-and-health-at-work/areasofwork/occupational-health/WCMS_868501/lang-en/index.htm)
4. The Royal Australian and New Zealand College of Radiologists. (2020, July 23). *Standards of Practice for Clinical Radiology, Version 11.2*. Retrieved May 30, 2023, from <https://www.ranzcr.com/college/document-library/standards-of-practice-for-clinical-radiology>
5. Australian Commission on Safety and Quality in Healthcare, Australian Government. (2016). *DIAS Practice Accreditation Standards*. Retrieved May 30, 2023, from <https://www.safetyandquality.gov.au/standards/diagnostic-imaging/diagnostic-imaging-accreditation-scheme-standards>
6. Australian Commission on Safety and Quality in Healthcare, Australian Government. (2016). *The Diagnostic Imaging Accreditation Scheme (DIAS)*. Retrieved May 30, 2023, from <https://www.safetyandquality.gov.au/standards/diagnostic-imaging/diagnostic-imaging-accreditation-scheme>
7. The Royal Australian and New Zealand College of Radiologists. (2013, November 1). *General X-ray QA and QC Guideline*. Retrieved May 30, 2023, from <https://www.ranzcr.com/college/document-library/general-x-ray-quality-assurance-and-quality-control-guidelines>
8. Medical Imaging and Technology Alliance. (2023). *Digital Imaging and Communications in Medicine (DICOM®) Standard*. Retrieved 30 May, 2023, from <https://www.dicomstandard.org/current/>

9. The Royal Australian and New Zealand College of Radiologists. (2018, June 22). *RANZCR Guidelines for Quality Control Testing for Digital (CR DR) Mammography*. Retrieved May 30, 2023, from <https://www.ranzcr.com/fellows/clinical-radiology/quality-assurance-and-accreditation/mgap>

Draft